INTERNATIONAL RESEARCH JOURNAL OF PHARMACY
www.irjponline.com
ISSN 2230 – 8407

Research Article

A PROSPECTIVE CROSS-SECTIONAL STUDY ON MANAGEMENT AND QUALITY OF LIFE ASSESSMENT USING VF-14 QUESTIONNAIRE IN PATIENTS WITH DIABETIC RETINOPATHY IN A TERTIARY CARE HOSPITAL

Syeda Zaineb Kubra Hussaini [1]*, Umesh Bhammarkar [2], Uppalanchi Ooha [3], Jangidi Usha Priya [3], Vankayalapati Poojitha Sri [3]
[1] Department of Pharmacy Practice, Malla Reddy Pharmacy College, Hyderabad, Telangana, India
[2] Head of Department of Ophthalmology, Sadhuram Eye Hospital, Hyderabad, India
[3] Doctor of Pharmacy, Malla Reddy Pharmacy College, Hyderabad, Telangana, India
*Corresponding Author Email: kubra687@gmail.com

Article Received on: 25/05/19 Approved for publication: 05/07/19

DOI: 10.7897/2230-8407.1009279

ABSTRACT

The aim of this study is to study the management and assess the vision related quality of life using VF-14 questionnaire for Diabetic Retinopathy (DR) among patients with Type 1 and Type 2 Diabetes. A prospective, cross sectional study was carried out on patients who were diagnosed to have Diabetic Retinopathy under the department of Ophthalmology of Sadhuram Eye Hospital, Hyderabad for 6 months. 100 patients with Type 1 and Type 2 Diabetes with NPDR, PDR, and patients above 18 years of age were recruited in the study. Data relevant to the vision related QOL study and management were obtained and recorded using VF-14 Questionnaire and data collection form respectively. Among 100 patients 65% of patients were males and 35% were females. The prevalence of DR was found to be more in the age group of (46-65) years. When the patients were categorized according to the duration of diabetes it was found that 50% were with (5-10 years) duration. When the samples were categorized based on the treatment undergone, it was found that most of the patients i.e. 34 % undergone therapy with bevacizumab followed by PRP. It was found that the mean QOL scores were improved after treatment with intra vitreal injections. Among samples collected it is shown that pharmacological agents that could slow the progression of Diabetic Retinopathy include anti-VEGF therapy and implantable dexamethasone which has been the new standard of care. The study analyzed that treatment provided was according to the standard therapeutic guidelines and overall QOL improved in patients with the treatment modalities.

Keywords: Diabetic Retinopathy, Quality of life, Macular Oedema.

INTRODUCTION

Diabetes Mellitus (DM) is a complex metabolic syndrome in which a relative or absolute insulin deficiency affects the metabolism of lipids, carbohydrates and proteins. The retina detects the light and converts it into signals sent through the optic nerve through the brain.[1]

Diabetic Retinopathy is considered a highly specific vascular complication for diabetes type 1 and diabetes type 2[2] and according to the American Diabetes Association (ADA) it is the leading cause of blindness in working age (25-65 years old), which occurs in one third of diabetic patients.[3]

Diabetic Retinopathy occurs because of the destruction of the small blood vessels feeding the retina and causes problems in receiving and sending images to the brain. This process is painless.[4]

Classification and Clinical features

Diabetic retinopathy progresses through two stages:

1. Non Proliferative Diabetic Retinopathy.
2. Proliferative Diabetic Retinopathy.

Non Proliferative Diabetic Retinopathy

1) Mild Non Proliferative Diabetic Retinopathy

Mild Non Proliferative Diabetic Retinopathy is characterized by at least one retinal micro aneurysm at fundoscopy. The vision is preserved and is not associated with clinically significant macular oedema. No other significant finding or abnormality is present.

2) Moderate Non Proliferative Diabetic Retinopathy

Moderate Non Proliferative Diabetic Retinopathy is characterized by micro aneurysms, haemorrhages, wool spots, vascular dilation (venous beading) and intraretinal micro vascular abnormalities (IRMA). Venous beading and IRMA can be present in a mild degree if compared to severe NPDR. The vision may be impaired due to clinically significant macular oedema and scatter photocoagulation is not indicated to treat moderate NPDR.

3) Severe Non Proliferative Diabetic Retinopathy

Severe NPDR is characterized by the presence of micro aneurysms, haemorrhages, cotton wool spots, venous beading and IRMAs in a higher degree of severity than moderate NPDR. The rule “4-2-1” can easily define severe PDR:

1. Microneurysms in 4 quadrants.
2. Venous bleeding in at least 2 quadrants (or)
3. IRMAs in 1 or more quadrants.

The findings of two of the above criteria in one eye are generally named severe NPDR. The risk of progression of very severe NPDR to high risk PDR is approximately 50% within 1 year and the ETDRS results suggest that scatter photocoagulation can be considered before onset of PDR.[5]

Proliferative Diabetic Retinopathy

Proliferative Diabetic Retinopathy is defined as the formation of abnormal neo vessels as an aberrant attempt to compensate retinal hypoxia in eyes with severe or very severe NPDR. Retinal ischemia leads to production of angiogenesis factors such as VEGF (vascular endothelial growth factor), BFGF (basic fibroblast growth factor), IGF-1 (insulin like growth factor 1) and other mediators which expression result on neovascularisation on stimulated tissue.[6-7]

1. **Early proliferative Diabetic retinopathy**

   Early PDR is defined as the presence of retinal neovascularisation that does not meet the criteria of high risk PDR as described on DR. Eyes with early PDR are frequently associated with macular oedema and also have a high rate of progression to high risk PDR.

2. **High risk PDR-proliferative Diabetic retinopathy**

   High Risk PDR is commonly related to severe visual loss due to PDR, and in its presence requires immediate scatter photocoagulation, as determined by Diabetic Retinopathy study. HR-PDR is characterized by any one or more of the findings:

- Disc neovascularisation (NVD) approximately 1/4 to 1/3 disc area in size with vitreous and/or pre retinal haemorrhage.
- NVD less than 1/4 disc area in size with vitreous and/or pre retinal haemorrhage.
- In patients with high risk PDR, bleeding from active neovascularisation can lead to vitreous haemorrhage, and frequently to severe vision loss. Patients who do not receive appropriate treatment to HR-PDR may evolve to tractional detachment a potentially blinding condition.

Treatment of Diabetic retinopathy

- Current treatment strategies for diabetic retinopathy are thought to be 90% effective in preventing severe vision loss.[8] Given the asymptomatic nature of diabetic retinopathy until its last stages and the effectiveness of early intervention,[9] referral for regular screening by an ophthalmologist is essential. The American Academy of Ophthalmology recommends Type 1 diabetes can be examined 3-5 years after diagnosis and yearly thereafter; type 2 diabetes should be examined at the time of diagnosis and yearly thereafter.[8]

- Primary prevention of diabetic retinopathy involves strict glycemic control and blood pressure control. The Diabetes Control and Complications trail[10] and the United Kingdom Prospective Diabetes study[11] showed that intensive glycaemic control substantially reduces the incidence and progression of diabetic retinopathy in type 1 and type 2 diabetes. Blood pressure control also significantly reduces the incidence and progression of diabetic retinopathy, although the specific anti hypertensive agent utilized does not appear to be significant.[12-13]

- Established secondary interventions for diabetic retinopathy include pan-retinal photocoagulation, focal laser photocoagulation, and surgical vitrectomy. Pan-retinal photocoagulation applies hundreds of laser burns to the peripheral retina, reducing the amount of ischemic retina that drives angiogenesis. Pan-retinal photocoagulation has been the cornerstone of treatment for severe retinopathy since the Diabetic Retinopathy Study, which showed that it reduces the risk of severe vision loss by 50% in patients with severe diabetic retinopathy.[14]

- Focal laser photocoagulation is indicated for patients with clinically significant macular oedema; it targets micro aneurysms near the macula, reducing the plasma leakage responsible for intra retinal swelling. The Early treatment Diabetic Study showed that focal laser photocoagulation reduces the risk of moderate vision loss by 50-70% in patients with macular oedema.[12]

- The central role of vascular endothelial growth factor in severe, vision threatening diabetic retinopathy warrants further investigation to determine if inhibitors of this protein will become part of routine care of diabetic retinopathy.

- Intravitreal triamcinolone acetonide also has received significant attention for the treatment of diabetic macular oedema. While triamcinolone does reduce macular thickness in the short term,[15] its 3 year visual benefit was found to be inferior to standard focal macular laser, with higher rates of glaucoma and cataract.[16]

Quality of life in Diabetic retinopathy

Quality of life, the degree to which an individual is healthy, comfortable and able to participate in or enjoy life events.[17]

The Quality of life in general is decreased in diabetic patients regardless of the gender. The patients with complications of diabetic retinopathy suffer from a variety of life style problems. In the end it leads to vision loss.

The visual function index (VF-14) questionnaire

The VF-14 was originally developed by Steinberg *et al*[18] as an index of visual function in patients undergoing cataract surgery. It has been tested and validated in patients with retinal disease including diabetic retinopathy.[19] briefly; respondents are first asked whether they have any difficulty with various vision-related tasks (e.g., reading, even with glasses, a newspaper or a book). A category of "not applicable" is included. If the answer to the lead in question is affirmative, the level of difficulty is placed on a 4 point scale (1= a little, 2= a moderate, 3= a great deal, 4= unable to perform activity). Scores for applicable items are averaged, and then inflated to a 0 to 100 scale.

Objectives

To assess the vision related quality of life and management in patients with Diabetic Retinopathy.

MATERIALS AND METHODS

A prospective, cross sectional study on management and assessment of QOL using VF - 14 questionnaires in patients with Diabetic Retinopathy was carried out for 6 months in Ophthalmology in outpatient department of Sadhuram Eye Hospital, Hyderabad, India. The questionnaire was administered to 100 patients to assess vision-related tasks.

Patients of either sex aged ≥18 years and above, patients who were diagnosed to have Type1 and Type 2 Diabetes are included in the study after obtaining an informed consent. Unconscious patients and patients with Gestational Diabetes were excluded from the study.

RESULTS

Among 100 patients 65% of patients were males and 35% were females. The prevalence of Diabetic Retinopathy was higher in the age group of 46-55 (37%). Macular Edema is present is total 63 (63%) of patients of which 45 (45%) and 18 (18%) were males and females respectively. According to the study, 2% of samples were within the age group of (8-25), 3% within (26-35), 13% within (36-45), 37% within (46-55), 33% within (56-65), 9% within (66-75) and 3% within (76-85). It was found that 56% of patients were positive and 34% were negative for family history of diabetes. When the patients were categorized according to the duration of diabetes it was found that 27% were with (< 5 years) of duration, 50% were with (5-10 years) and 23% were with (> 10 years). Of the total patients 31% of patients were advised to take OCT scan, 38% CP + OCT scan, 14% FA + OCT scan , 14% B-Scan ultrasound + OCT and 6% with CT + B-Scan + OCT. When the samples were categorized based on the treatment undergone, it was found that 14% undergone therapy with intravitreal injections (Bevacizumab and dexamethasone), 16% undergone PRP, 7% undergone vitrectomy surgery, 34% undergone therapy with intravitreal injections and grid therapy, 7% undergone PRP + Vitrectomy + bevacizumab, 13% were advised with eye drops and Glycaemic control. The present study categorized the patients based on their treatment modalities with their respective Mean QOL scores.

Table 1: Distribution of patients based on the gender

S. No.	Gender	No. of Patients	Frequency
1.	Males	65	65%
2.	Females	35	35%

Table 2: Distribution of patients based on presence or absence of macular oedema

S. No.	Macular edema	
	Present	Absent
Male	**45 (45%)**	**20 (20%)**
Female	**18 (18%)**	**17 (17%)**

Table 3: Duration of diabetes

S. No.	Duration of diabetes	Sex	NO. OF Patients
1.	<5 YEARS	M	15 (15%)
		F	12 (12%)
2.	5-10 YEARS	M	36 (36%)
		F	14 (14%)
3.	>10 YEARS	M	14 (14%)
		F	9 (9%)

Table 4: Diagnosis of Diabetic retinopathy

S. No.	Diagnosis	Gender	No. of patients
1.	OCT	M	28 (28%)
		F	3 (3%)
2.	CP + OCT	M	21 (21%)
		F	17 (17%)
3.	FA + OCT	M	5 (5%)
		F	5 (5%)
4.	B-Scan Ultrasound + OCT	M	9 (9%)
		F	4 (4%)
5.	CT + B-Scan + OCT	M	2 (2%)
		F	6 (6%)

Optical coherence tomography, Fluorescein angiography

Table 5: Severity of Diabetic retinopathy

S. No.	Stages	Degree of visual impairment	VF-Score	No. of patients	
1	PDR	Very severe	0-9	M	19 (19%)
				F	12 (12%)
2	Severe NPDR	Severe	10-29	M	27 (27%)
				F	2 (2%)
3	Moderate NPDR	Moderate	30-74	M	13 (13%)
				F	13 (13%)
4	Mild NPDR	Mild	75-92	M	6 (6%)
				F	8 (8%)

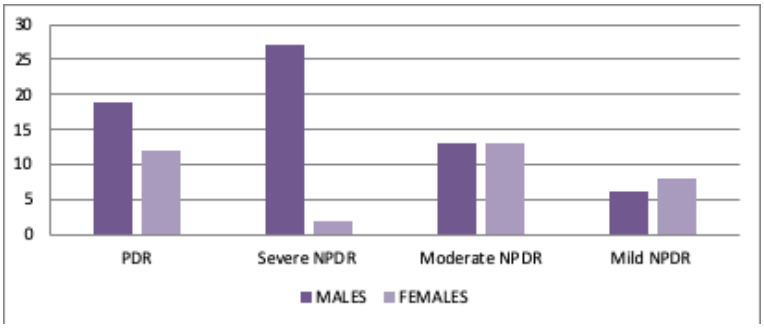

Figure 1: Graphical representation of Severity of Diabetic retinopathy

Table 6: Mean QOL Score (Initial and final visit) with different treatment regimens

S. No.	Treatment undergone	No. of patients		Mean QOL Score (VF-14 Score)		Change in QOL Score
		M	F	before treatment	after treatment	
1.	Intravitreal injections (Bevacizumab, Dexamethasone)	8	6	37..07	53.21	16.14
2.	GRID + PRP	9	7	25.07	42.63	17.56
3.	PRP followed by vitrectomy surgery	9	4	14.01	36.98	22.97
4.	Intravitreal Bevacizumab + Grid + PRP	13	9	29.46	40.32	10.86
5.	Intravitreal Dexamethasone + Grid + PRP	6	3	29.63	42.88	13.25
6.	Intravitreal Ranibizumab + Grid + PRP	4	1	19.19	30.9	11.71
7.	Intravitreal Bavacizumab + PRP + vitrectomy surgery	4	3	11.71	20.6	8.89
8.	Eye drops + Glycemic control	9	5	69.17	90.14	20.97

PRP - PAN retinal photocoagulation

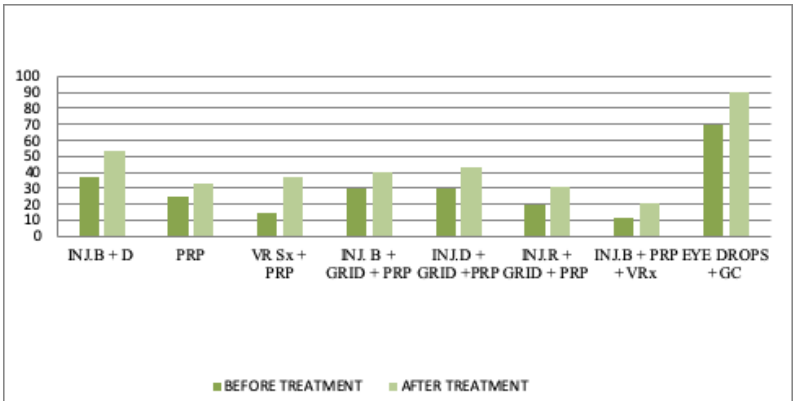

Figure 2: Graphical representation of Mean QOL scores (Initial and final visit) with different treatment regimens
Inj. B + D - Intravitreal Bevacizumab + Dexamethasone, PRP - Pan Retinal Photocoagulation, VRSX - Vitrectomy Surgery, Inj. R - Intravitreal Ranibizumab, Inj. D - Intravitreal Dexamethasone, GC - Glycaemic control

CONCLUSION

Diabetic Retinopathy severely affects quality of life for patients with diabetes by decreasing VA and increasing the risk of blindness. There is substantial evidence that control over metabolic factors can effectively prevent the development and progression of DR/DME. However, many patients fail to achieve or maintain optimal levels of metabolic control. For such patients, early detection and timely treatment of DR remains the standard of care. Among samples collected it is shown that pharmacological agents that could slow the progression of DR/DME in earlier stages include anti- VEGF therapy and implantable dexamethasone which has been the new standard of care.The study analyzed that treatment provided was according to the standard therapeutic guidelines and overall QOL improved in patients after treatment. It is likely that one or more of these pharmacological interventions, or possibly combinations thereof, will be effective in reducing the progression of DR and DME and the associated vision loss. Technological advances are giving patients more access to proper screening and may make this a more achievable goal.

REFERENCES

1. www.medscape.com/diabetic retinopathy
2. Askari M, Hajizadeh E, Afkhami M. A survey of effective causes on Retinopathy in Type 2 Diabetic patient. Journal of Tehean University of Medical Sciences 2011; 3(1): 2-13(Persian)
3. Ashraf H, Afraid M, Shahrzads. Situation of follow up in diabetic retinopathy of patients refers to Shiraz University Center. Journal of Southern Medical 2010; 13(4): 280-286.
4. Smeltzer S. Brunner and Suddarth textbook of medical surgical nursing. 12th Ed. Translated by: DabiranA, Shaban M. Tehran: Andisherafi; 2010.(Persian)

5. Early Treatment Diabetic Retinopathy Study: Early photocoagulation for diabetic retinopathy. ETDRS report number 9. Ophthalmology 1991; 98: 766-85.
6. Diabetic Retinopathy Study Research Group: Photocoagulation treatment of Proliferative diabetic retinopathy: clinical application of diabetic retinopathy study (DRS) Report number 8. Ophthalmology 1981; 88: 583-600.
7. Diabetic Retinopathy Study Research Group: Photocoagulation treatment of proliferative diabetic retinopathy: relationship of adverse treatment effects to retinopathy severity.
8. American Academy of Ophthalmology Retina Panel. Preferred Practice Pattern Guidelines. Diabetic Retinopathy. San Francisco, CA: American Academy of Ophthalmology; 2008.
9. Early Treatment Diabetic Retinopathy Study Research Group. Early photocoagulation for diabetic retinopathy. ETDRS report number 9. Ophthalmology 1991; 98: 766-785.
10. UK Prospective Diabetes Study (UKPDS) Group. Intensive blood glucose control with sulphonylureas or insulin compared with conventional treatment and risk of complications in patients with type 2 diabetes. Lancet 1998; 352(19131): 837-853.
11. Matthews DR, Stratton IM, Aldington SJ, *et al*. Risks of progression of retinopathy and vision loss related to tight blood pressure control in type 2 diabetes mellitus: UKPDS 69. Arch Ophthalmol 2004; 122: 1631-1640.
12. Estacio RO, Jeffers BW, Gifford N, *et al*. Effect of blood pressure control on diabetic micro vascular complications in patients with hypertension and type 2 diabetes. Diabetes care 2000; 23(Suppl 2): B54-B64.
13. Indications for photocoagulation treatment of diabetic retinopathy. The Diabetic Retinopathy Study Research Group. Int Ophthalmol Clin 1987; 27: 239-253.
14. The Diabetic Retinopathy Vitrectomy Study Research Group. Early Vitrectomy for severe vitreous haemorrhage in diabetic retinopathy. Four-year results of a randomized trial. Arch Ophthalmol 1990; 108: 958-964.
15. Yilmaz T, Weaver CD, Gallagher MJ, *et al*. Intravitreal triamcinolone acetonide injection for treatment of refractory diabetic macular oedema: A systematic review.
16. Ophthalmology 2009; 116: 902-911.
17. Vision problem in the US: Prevalence of Adult Vision Impairment and Age-Related Eye Disease. National Eye Institute and Prevent Blindness in America www.nci.nih.gov/eyedata/pdf VPUS. pdf; 2002.
18. Chamberline J. Janiszewski R. Diabetic Retinopathy occurs in Pre-Diabetes http://www.nih.gov/news/pr/jann2005/niddk-12.htm; 2002.
19. DCCT Research Group. The effect of Intensive Treatment of Diabetes on the Development and Progression of Long Term Complications in Insulin-dependent Diabetes Mellitus. NEIM 1993; 329: 977-860.

Cite this article as:

Syeda Zaineb *et al*. A Prospective Cross-Sectional Study on Management and Quality of life assessment using Vf-14 Questionnaire in patients with Diabetic Retinopathy in a Tertiary Care Hospital. Int. Res. J. Pharm. 2019;10(9):182-186 http://dx.doi.org/10.7897/2230-8407.1009279

Source of support: Nil, Conflict of interest: None Declared