INTERNATIONAL RESEARCH JOURNAL OF PHARMACY **ISSN 2230 – 8407**
Available online http://www.irjponline.com
Research Article

WOUND HEALING ACTIVITY OF ETHANOL EXTRACT OF *PSEUDARTHRIA VISCIDA* LINN

M. Vijayabaskaran*, P. Sajeer, P. Perumal
Department of Pharmaceutical Chemistry, J.K.K Nataraja College of Pharmacy, Natarajapuram, Salem main road, Komarapalayam, Namakkal, Tamilnadu, India

Article Received on: 19/02/2011 Revised on:02/04/2011 Approved for publication:14/04/2011

*E mail: vijayabass@gmail.com

ABSTRACT
The wound healing activity of topically applied ethanol extract of *Pseudarthria viscida* was evaluated in wistar rat by excision wound model for a period of 12 days. The extract was prepared as ointment form (5 and 10% w/w) and applied on Wistar rats. Neomycin ointment 0.5%w/w was used as standard drug. The healing of the wound was assessed by the rate of wound contraction, period of epithelialisation, skin breaking strength. Both the ointments (5% and 10% w/w) of *Pseudarthria viscida* extract promoted the wound-healing activity significantly when compared to the standard drug. High rate of wound contraction, decrease the period for epithelialisation, high skin breaking strength were observed in animals treated with 10% w/w extract ointment when compared to the control group of animals. So ethanol extract of *Pseudarthria viscida* in the form of 10% ointment promote wound-healing activity better than the former concentration, 5%. The result obtained from this study indicates that ethanol extract of *Pseudarthria viscida* accelerates the wound healing process by decreasing the surface area of the wound.
KEYWORDS: Excision wound model, Epithelialisation, Neomycin ointment**,** *Pseudarthria viscida*, topically applied, Wound healing.

INTRODUCTION

A wound which is disrupted state of tissue caused by physical, chemical, microbial or immunological insult ultimately heals either by regeneration or fibroplasias[1]. Wound healing is a complex process that result in the contraction and closure of the wound and restoration of a functional barrier (1) Cutaneous wound repair is accompanied by an ordered and definable sequence of biological events starting with wound closure and progressing to the repair and remodeling of damaged tissue (2) Repair of injured tissues includes inflammation, proliferation, and migration of different cell types (3) Inflammation, which constitutes a part of the acute response, result in a coordinated influx of neutrophils at the wound site[2].

The plant *Pseudarthria viscida* Linn (family: Fabaceae) is useful in vitiated conditions of pitta and vata, cough, bronchitis, asthma, tuberculosis, helminthiasis, dyspepsia, inflammation, cardiopathy, haemorrhoids, gout, hyperthermia and general debility[3-5]. The plant has shown to possess antifungal[6], antioxidant[7], anti-tumor[8], anti hypertensive[9] and antidiarrhoeal[10] activities. Since no information is available on the wound healing activity of *Pseudarthria viscida*. The presnt study was undertaken to investigate the wound healing effect of ethanol extract of *Pseudarthria viscida* (EEPV).

MATERIALS AND METHODS

The plant *Pseudarthria viscida* Linn (Family: Fabaceae) was collected from Kolli hills, Namakkal District, Tamilnadu, India. The plant material was taxonomically identified by the botanical survey of India, Southern circle, TNAU Campus, Coimbatore, Tamilnadu (NO/BSI/SC/5/23/06-07/tech-166).

Preparation of the extract

The whole plant of *Pseudarthria viscida* Linn was dried under shade, and made in to a coarse powder with a mechanical grinder. The coarse powder was passed through sieve no: 40 and stored in an airtight container for further use. The dried powder material was defatted with petroleum ether (60-80ºC) by using soxhlet extractor to remove waxy substances and chlorophyll, which usually interfere in the isolation of phytoconstituents. The marc, defatted with petroleum ether was dried and extracted by using ethanol (99.9%v/v) in a soxhlet extractor for 72 hr. The solvent was then distilled off and the resulting semisolid mass was dried in a dessicator to get a yield of **4% w/w.**

Phytochemical analysis of the extract

The extract was screened for the presence of various constituents employing standard screening tests[11]. Conventional protocols for detecting the presence of secondary metabolites such as glycosides, saponins,

flavonoids, tannins were used. Several phytoconstituents like flavonoids, terpenoids and Tannins are known to promote wound healing process due to their antioxidant and antimicrobial activities.

Experimental animal

All the experiments were carried out according to the guidelines of the committee for the purpose of control and supervision of experiments on animals (CPCSEA), New Delhi, India and approved by Institutional Animal Ethical Committee. (Regd. No: 997 /c /06 / CPCSEA).

Wistar rats of either sex weighing 150-200g were used for the study. On arrival, the animals were placed randomly and allocated to treatment groups in poly propylene cages (47×34×18cm) with paddy husk as bedding. It was renewed every 24h. Animals were housed at a temperature of 24 ± 2°C and relative humidity of 30-70% and light : dark (12:12h) cycle was followed. All the animals were allowed to free access to water and fed with standard commercial pelleted chew (M/s. Hindustan Lever Ltd., Mumbai). The standard pellet diet comprised 21% protein, 5% lipids, 4% crude fibre, 8% ash, 1% calcium, 0.6% phosphorus, 3.4% glucose, 2% vitamin and 55% nitrogen free extract (carbohydrates). It provides metabolisable energy of 3,600 kcal.

Wound healing activity by Excision Wound model

Animals were anaesthetized by open mask method with anaesthetic ether, the rats were depilated on the back and a predetermined area of about 500mm^2 and full thickness skin was excised in the dorsal inter scapular region. The animals were divided in to four groups of six each. The animals of group 1 were left untreated and considered as control, group 2 served as reference standard and treated with 0.5% w/w Neomycin ointment. Animals of group 3 and 4 were treated with 5%w/w and 10%w/w prepared EEPV ointments respectively. The ointment was topically applied once a day, starting from the first day of operation. The progressive changes in wound area were measured plan metrically by tracing the wound margin on a graph paper at alternate days 3, 6, 9 and 12. The change in wound healing, measurement of wound area on graph paper was expressed as unit mm^2 and the percentage of wound closure was calculated.[12-20].

Statistical Analysis

All the results were expressed as mean ± standard error mean (S.E.M). Data were analyzed statistically by using one-way ANOVA followed by Dunnet's test. The minimum level of significance was set at $P < 0.05$. All the analysis was conducted in triplicate and statistical analysis by using Graph pad prism software of version 5.

RESULTS

In the present study the rate of wound contraction by excision wound model was studied. The area of wound in sq. mm at different time interval is given in Table **1** and Graph 1. Percentage reduction in the area of the wound at different time interval is given in the Table 2 and Graph 2.

The mean percentage closure of wound area was calculated on 3, 6, 9 and 12th post wounding days as shown in Table 1 & 2. The doses of 5% and 10% w/w EEPV treated animals were showed significant percentage wound contraction of 90.30% and 92.71% respectively when compared with the control group having activity of 76.27%. The wound healing activity of standard group received Neomycin was observed as 95.19%. The results revealed that, the wound healing activity of EEPV were comparable to standard Neomycin ointment (0.5% w/w).

DISCUSSION

Wound healing is a complex sequence of events, is initiated by the stimulus of injury to the tissues. A positive stimulus may result from the release of some factors by wounding of tissues. Cutaneous wound repair is accompanied by an ordered and definable sequence of biological events starting with wound closure and progressing to the repair and remodeling of damaged tissue. Wound healing effect is also attributed to free radical scavenging activity of flavonoids. Flavonoids are known to reduce lipid peroxidation not only by preventing or slowing onset of cell necrosis, but also by improving vascularity. Lipid peroxidation is an important process in several types of injuries like burns, infected wounds and skin ulcers. Hence any drug that inhibits lipid peroxidation is believed to increase strength of collagen fibres, by increasing circulation or by preventing cell damage or by promoting DNA synthesis.

Many plant extracts and medicinal herbs have shown potent antioxidant activity. Flavonoids, the main components of many plant extracts, act as free radical scavengers. Research into the role of antioxidants from plant extracts in wound healing has been published widely. Wound healing process consists of different phases such as granulation, collagenation, collagen maturation and scar maturation which are concurrent but independent to each other.

The result of present study indicates that, ointment of EEPV at both strengths (5% and 10%) exhibited significant wound healing promoting activity. However, this effect was found to be concentration related fashion where 10% ointment promotes significant wound-healing activity by increasing cellular proliferation, formation of

granulation tissue, synthesis of collagen and by increase in the rate of wound contraction as compared to the control animals. Presence of flavonoids and tannins in EEPV may be responsible for its wound healing activity. The flavonoids were responsible for the free radical scavenging activity were believed to be one of the important components in wound healing. The EEPV showed a significant activity when compared with the standard drug Neomycin ointment. This revealed the flavonoids present in the EEPV may be responsible for the wound healing activity.

On the basis of the results obtained in the present investigation, it is possible to conclude that the activity of EEPV at 5% w/w and 10% w/w ointment was in a dose dependent manner and was found to be statistically significant at higher doses when compared to the effect produced by standard drug Neomycin (0.5%w/w) in excision wound model.

CONCLUSION

In the present study on extract of *Pseudarthria viscida* showed marked reduction in wound area in comparison to control group when examined for wound healing activity by topical application in wistar rats. Promissing results appeared from 3rd day onwards in a 12 days study using excision wound model on rats, indicates that the ethanol extract of *Pseudarthria viscida* accelerates the wound healing process by decreasing the surface area of the wound.

REFERENCES

1. Padmaa M Paarakh, Chansouria J P N, KhosaR L; Wound healing activity of *Annona muricata* extract. Journal of Pharmacy Research 2009; 2(3):404-406.
2. Bele A A, Jadhav V M, Kadam V J; Wound healing activity of herbal formulation. Journal of Pharmacy Research 2009; 2(3):344-348.
3. Nadkarni KM. Indian Materia Medica. Popular Prakashan, Pvt. Ltd, Bombay, 1976; 1: 1017.
4. Sivarajan VV and Indira Balachandran. Ayurvedic drugs and their plant sources. Oxford and IBH publishing co. Pvt. Ltd, New Delhi. 1994; 1st ed: 414.
5. Warrier PK, Nambiar VPD, Ramankutty C. Indian Medicinal Plants. Orient Longman Ltd, Chennai, 1995; 2 : 366.
6. Deepa MA, Narmatha Bai, V. Basker S. Antifungal properties of *Pseudarthria viscida*, Fitoterapia. 2004; 75 : 581-584.
7. Gincy M Mathew and Sasikumar JM, Antioxidant activity of *Pseudarthria viscida*. Indian Journal of Pharmaceutical Science. 2007; 69(4): 581-582.
8. Vijayabaskaran M, Sivakumar P, Sambathkuamr R, Perumal P, Sivakumar T, and Jayakar B. Antitumor and antioxidant activities of *Pseudarthria viscida* against Dalton's ascites lymphoma bearing swiss albino mice, Research journal of Pharmacy and Technology 2008; 1(3): 225-229.
9. Hansen Klaus, Nyman U, Ulla Wagner Smitt, Anne Adsersen, Sreedharan Rajasekharan and Palpu Pushpangadan. In vitro screening of traditional medicines for anti-hypertensive effect based on inhibition of the angiotensin converting enzyme (ACE). Journal of Ethnopharmacology. 1995; 48 (1): 43-51.
10. Vijayabaskaran M, Venkateswaramurthy N, Babu G and Khatale PN. Antidiarrhoeal activity of *Pseudarthria viscida* roots. International Journal Of Pharmacy&Technology. 2010; 2(2): 307-313.
11. Trease GE, Evans WC, Text book of Pharmacognosy, Edn 12, ELBS Publication, Bailliere Tindall 1985, 334-345.
12. A Choudary GP. Evaluation of wound healing activity of galls of *Quercus infectoria.* Asian Journal of Chemistry. 2007; 19(4): 3271-3273.
13. Chitra Shenoy, Patil MB, Ravi kumar, Swati Patil. Preliminary phytochemical investigation and wound healing activity of *Allium cepa* Linn. International Journal of Pharmacy and Pharmaceutical Sciences. 2009; 2: 167-175.
14. Shivananda B Nayak, Steve Sandiford and Anderson Maxwell. Evaluation of the wound-healing activity of ethanolic extract of *Morinda citrifolia* L. Leaf. E cam. 2007; 6(3): 351–356.
15. Shanbhag Tara V, Sharma Chandrakala, Adiga Sachidananda, Bairy Laxminarayana Kurady, Shenoy Smitha, Shenoy Ganesh. Wound healing activity of alcoholic extract of *Kaempferia galanga* in rats. Indian Journal of Physiology and Pharmacology. 2006; 50(4): 384–390.
16. Barua CC, Talukdar A, Begum SA, Sarma DK, Pathak DC, Barua AG, Bora RS. Wound healing activity of methanolic extract of leaves of *Alternanthera brasiliana* Kuntz. Indian Journal of Experimental Biology. 2009; 47: 1001-1005.
17. Sheeba M, Emmanuel S, Revathi K, Ignacimuthu S. Wound healing activity of *Cassia occidentalis*. International Journal of Integrative Biology. 2009; 8(1): 1-6.
18. Nayak S, Nalabothu P, Sandiford S, Vidyasagar B, Andrew A. Evaluation of wound healing activity of *Allamanda cathartica. L.* and *Laurus nobilis. L.* extracts on rats. BMC Complementary and Alternative Medicine. 2006; 6: 12-16
19. Choudary GP. Wound healing activity of ethanolic extract of *Terminelia bellirica* Roxb fruits. Natural products radiance. 2008; 7(1): 19-21.
20. Nalesh Malviya, Sanjay Jain. Wound healing activity of aqueous extract of *Radix paeoniae* root. Acta Poloniac Pharmaceutical Drug Research. 2009; 66(5): 543-547.

Table 1 . Area of wound in sq. mm at different time interval

Groups	Wound Area (mm^2)				
	Day 0	Day 3	Day 6	Day 9	Day 12
Control	160.6 ± 1.5	152.5 ± 1.3**	103.5 ± 1.2	55.1 ± 2.3	38.1 ± 3.0
Standard (Neomycin - 0.5%w/w)	162.0 ± 1.9	113.3 ± 1.7***	44.1 ± 1.7***	21.8 ± 1.0***	7.83 ± 1.3***
EEPV (5% w/w)	162.8 ± 1.5	140.0± 1.9**	77.1 ± 1.5**	35.0 ± 0.8**	15.8 ± 1.5***
EEPV (10% w/w)	161.8 ± 1.9	127.0 ± 1.5**	62.1 ± 1.4**	28.5 ± 0.9***	11.8 ± 1.2***

Results are expressed in Mean ± SEM; * P<0.05, **P<0.01 and ***P< 0.001.

Table 2: Percentage reduction in the area of the wound at different time interval

Groups	% Wound Area Contraction			
	Day 3	Day 6	Day 9	Day 12
Control	5.04	35.55	65.69	76.27
Standard (Neomycin - 0.5% w/w)	30.06	72.78	86.54	95.19
EEPV (5% w/w)	14.01	52.64	78.5	90.30
EEPV (10% w/w)	21.51	61.62	82.39	92.71

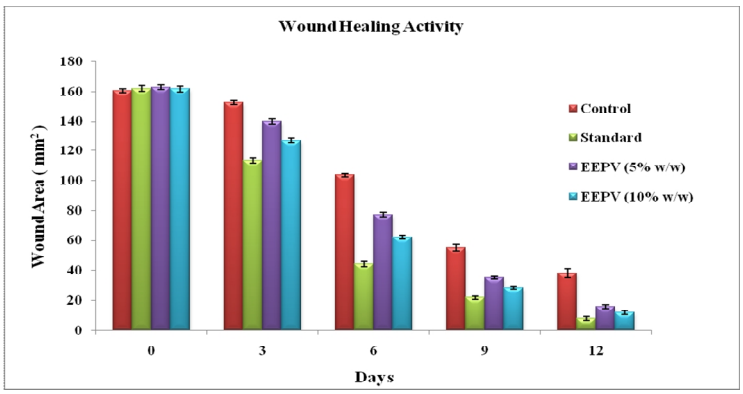

Graph: 1

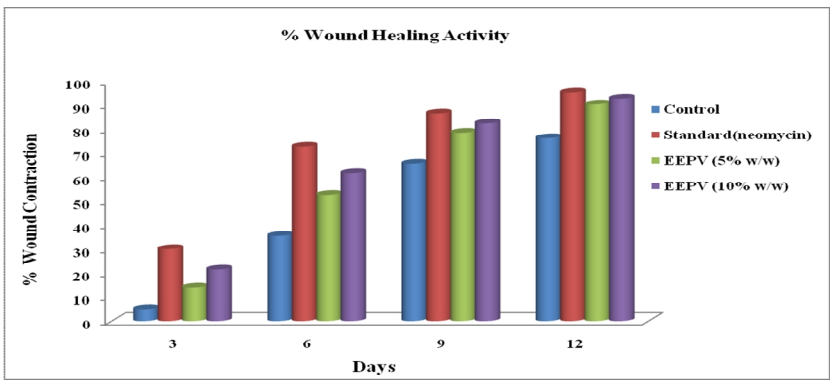

Graph: 2

Source of support: Nil, Conflict of interest: None Declared