



Review Article

PEMPHIGUS VULGARIS: AN UPDATE ON ETIOPATHOGENESIS, CLINICAL MANIFESTATIONS, DIAGNOSIS AND TREATMENT MODALITIES

Shamimul Hasan ^{1*}, Sameer Ahmed ², Ravi Kiran ³

¹Assistant Professor, Department of Oral Medicine and Radiology, Faculty of Dentistry, Jamia Milia Islamia, New Delhi

²Reader, Department of Periodontology, Darshan dental college and Hospitals Udaipur, Rajasthan, India

³Professor & Head of Department, Department of Periodontology, Darshan dental college and Hospitals Udaipur, Rajasthan, India

*Corresponding Author Email: shamim0571@gmail.com

Article Received on: 21/12/18 Approved for publication: 30/01/19

DOI: 10.7897/2230-8407.100369

ABSTRACT

Pemphigus Vulgaris is an autoimmune, mucocutaneous disorder characterized by occurrence of multiple chronic ulcerations. Although exact etiology is still obscure, the underlying pathogenesis in Pemphigus vulgaris involves autoimmune attack on the epithelial cell adhesion molecules, namely desmosomes and hemidesmosomes. Oral lesions generally appear before the onset of skin lesions, and in 60-70% cases, oral lesions may be the only presenting symptoms. The initial oral lesions manifest as thin walled flaccid bullae, which eventually rupture, leading to formation of large erosive lesions. Early and accurate diagnosis is extremely essential and entails a meticulous history taking, thorough oral and systemic examination along with characteristic histopathology and immunofluorescence features. Although corticosteroids are still the cornerstone of pharmacotherapy, a number of emerging therapies have also evolved with good results.

KEYWORDS: Acantholysis, corticosteroids, erosions, pemphigus, nikolsky sign

INTRODUCTION

Pemphigus refers to a group of autoimmune epithelial blistering mucocutaneous disorder and the term pemphigus is a derivative from the Greek word *Pemphix* (blister or bubble)^{1,2}.

Pemphigus vulgaris (PV) is the most frequently seen type of pemphigus in Europe and North America³. Pemphigus foliaceus, a different type of pemphigus is further subtyped as-idiopathic pemphigus foliaceus, drug induced pemphigus foliaceus, pemphigus erythematosus (senear usher syndrome) and endemic pemphigus foliaceus or fogo selvage (endemic to Brazil and Columbia).

Pemphigus vegetans is a subtype of pemphigus vulgaris associated with excessive granulation tissue and crusting⁴. Paraneoplastic pemphigus is associated with underlying malignancies⁵.

Acantholysis is a distinguishing histologic picture of the pemphigus group, with formation of characteristic intra-epithelial bullae⁶. There is histological difference in the acantholysis pattern in Pemphigus vulgaris and pemphigus foliaceus. Acantholysis occurs in the lower stratum spinosum in pemphigus vulgaris, however, pemphigus foliaceus is associated with acantholysis occurring more superficially in the stratum spinosum⁷.

Pemphigus vulgaris is a chronic, intra-epithelial vesiculo-bullous disease with a potentially lethal outcome⁸, and described initially by Wickman in 1791⁹. Highlighting features of pemphigus vulgaris are-chronic course, and vesiculo-bullous eruptions and eventual erosions involving the muco-cutaneous surfaces¹⁰. High mortality rates are linked with geriatric patients and in individuals necessitating corticosteroid doses who develop infections and bacterial septicemia, mostly from *Staphylococcus aureus* (fluid and electrolyte loss)¹¹.

ETIOPATHOGENESIS

The exact etiology of PV is obscure. PV may have a genetic predilection due to its association with certain ethnic groups (Ashkenazi jews and people of Mediterranean people)¹².

Various predisposing factors are-

1. Diet- Diet has been mentioned as an etiological agent in few studies^{13,14}, however, excessive garlic intake may be associated with few reported pemphigus cases¹⁵.
2. Drugs¹⁶- A wide array of drugs may also induce pemphigus lesions.

Angiotensin-converting enzyme (ACE) inhibitors	Thiol antibiotics	Anti-inflammatory drugs	Miscellaneous
Captopril	Cephalosporin	Aspirin	Levodopa
Cilazapril	Penicillamine	NSAIDs	Nifedipine
Enalapril	Penicillin (benzyl)		Propranolol
Fosinopril			Rifampicin
Ramipril			

3. Viruses- Viruses have been implicated as a possible etiologic factor as some fogo selvagem variant of pemphigus has contagious character¹⁷. Herpes virus infections has been linked with PV lesions¹⁸, and the proposed primary pathogenesis involves epitope spreading or molecular impersonation¹⁹. Human herpes virus 8 (HHV-8) DNA has been isolated in individuals with PV lesions^{20,21}.

4. Miscellaneous factors- Other precipitating factors associated with PV are- imprudent pesticides exposure and increased episodes in pregnancy, thus, highlighting the role of estrogens in the disease pathogenesis²².

PV pathogenesis involves an autoimmune attack against desmosomes and hemidesmosomes accountable for epithelial cell adherence. Desmogleins are the proteins that are reactive to autoimmune antibodies in PV. Enzyme-linked immunosorbent assay (ELISA) techniques can demonstrate circulating antibodies involving desmogleins²³. Three types of desmoglein proteins are demonstrable in stratified squamous epithelium (type 1,2 and 3). In skin and mucosa, desmoglein type 1 is identified in suprabasal cell layers, desmoglein type 2 is seen in the basal cell layer, and desmoglein type 3 appears in the basal and immediate suprabasal layer²³. In oral mucosa, desmoglein type 1 is expressed minimally. Hence, raised antibody titres to desmoglein type 1 and 3 are associated with cutaneous lesions, whereas predominant oral lesions are seen with desmoglein type 3. Recent studies revealed that epitope switching from oral PV with desmoglein type 3 antibodies to mucocutaneous disease occurs, hence, the presence of antibodies to both desmoglein types 1 and 3^{24,25}.

The differing sites of involvement noted clinically can be elegantly explained by the theory of desmoglein (DSG) compensation. Dsg1 and Dsg3 compensate their adhesive function when co-expressed on the same cell. It has been

suggested that the distribution and expression levels of Dsg1 and Dsg3 might account for the characteristic blisters distribution and localization in PV and PF patients. Microscopic studies have demonstrated the expression of Dsg 3 all through the oral mucous membranes, more pronounced in the upper two-thirds. However, the expression of Dsg 3 is limited to the basal and immediate suprabasal layers in the epidermis. This is in contrast to Dsg1, which is expressed throughout the epidermis and oral mucosa, but more pronounced expression occurs in the subcorneal layer and very feeble in the deep epidermis. (Fig 1: A1,B1). The antidesmoglein autoantibody profile in PV is responsible for the respective clinical phenotype. Some PV patients may demonstrate anti-Dsg3 IgG, whereas both anti-Dsg3 and anti-Dsg1 IgG may be demonstrated in other PV patients. However, only anti-Dsg1 IgG have been noticed in patients with PF. The specific site for blister formation in PV may be well explained by the expression of anti-Dsg1 IgG and anti-Dsg3 IgG (Fig 1: A1,B1). This also explains the reason of acantholysis occurring in the deepest mucosal layers (minimal Dsg1 expression) and not in the cutaneous layers (High Dsg1 expression) (Fig. 1: A2, B2). Hence, only oral erosive lesions occurs with no apparent cutaneous lesions in Mucosal dominant Pemphigus Vulgaris. Moreover, both anti-Dsg1 and antiDsg3 antibodies may be demonstrated in Mucocutaneous PV, thus, ‘low acantholysis’ in the epidermis may also take place (Fig 1: A3, B3). It is not clear that why the split occurs just above the basal layer instead of the whole epithelium falling apart. However, fewer desmosomes between the basal and the immediate suprabasal layers may be suggested as a reason for a weaker the cell–cell adhesion in this epidermis part. The autoantibodies penetrating from the demis may have an improved entry to the the lower part of the epidermis, thus, explaining the suprabasilar splits in mucocutaneous PV²⁶.

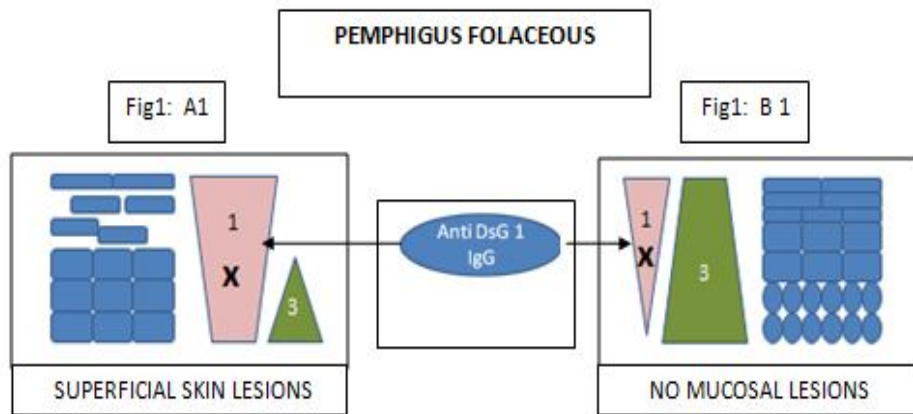


Figure 1. (A1, B1) Explanation of localization of vesicle formation in classic pemphigus by desmoglein compensation theory. The coloured triangles represent the distribution of desmoglein (Dsg 1) and desmoglein 3(Dsg 3) in the skin and mucous membrane. Pemphigus foliaceus sera contain only anti Dsg 1 , which causes superficial blisters in the skin because Dsg3 functionally compensates for the impaired Dsg 1 in the lower part of the epidermis (A 1), whereas those antibodies do not cause blisters in the mucous membranes because cell-cell adhesion is mainly mediated by Dsg3(B1).

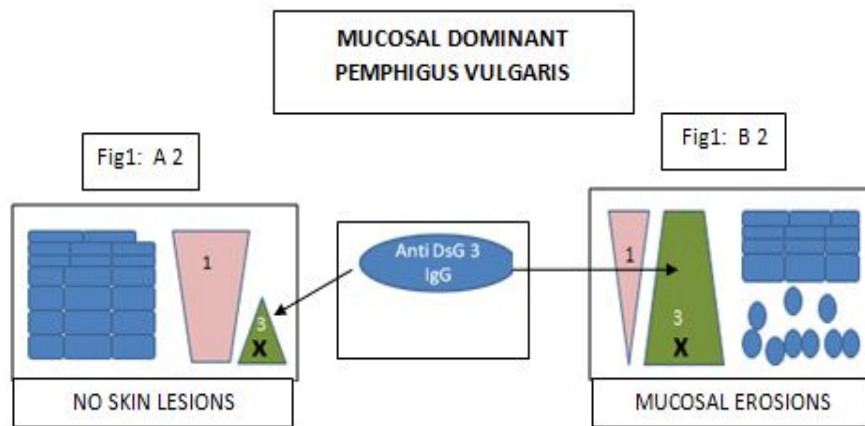


Figure 1 (A2, B2) Sera containing only anti –Dsg 3 IgG causes no or only limited blisters in the skin because Dsg 1 compensates for the loss of Dsg 3 mediated adhesion (A 2) ; however, these sera induce separation in the mucous membranes, where the low expression of Dsg 1 will not compensate for the loss of Dsg3 mediated adhesion (B2).

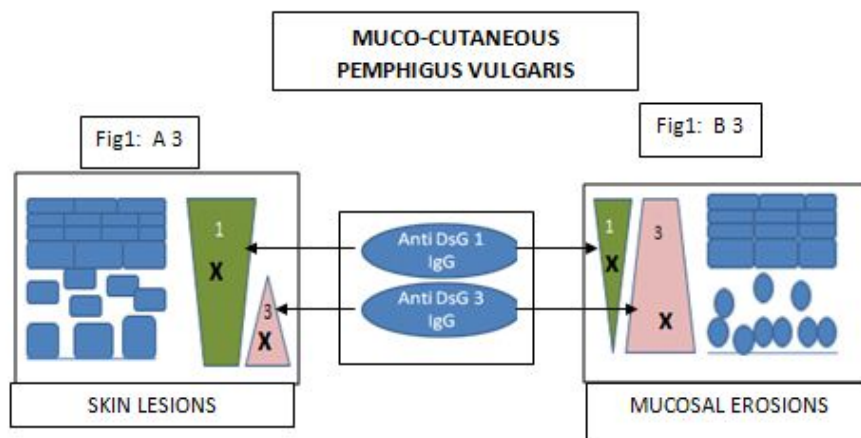


Figure 1 (A3,B3) When sera contains both anti Dsg 1 and anti Dsg3 IgG, the function of both Dsgs is compromised and blisters occur in both the skin and mucous membranes (A 3 and B 3) . In neonatal skin, the situation is similar to that shown here for mucous membranes.

(Figure 1 (A1,B1;A2,B2;A3,B3) Courtesy: Siddiqui S, Haroon MA, Hasan S, Khalid A. To Determine Desmoglein Compensation Theory: An explanation for early appearance of oral lesions as compared to skin lesions in Pemphigus vulgaris. International Archives of BioMedical and Clinical Research 2016; 2(3): 13-17.

CLINICAL MANIFESTATIONS

PV frequently involve the mucocutaneous sites, resulting in superficial blistering and persistent ulcerative lesions. Multiple mucosal sites are affected, namely, ocular mucosa, oral mucosa, nasal mucosa, pharyngeal and laryngeal mucosa, upper respiratory tract mucosa and ano-genital mucosa²⁷.

The hallmark clinical picture of PV consist of thin walled vesiculo-bullous lesions, which eventually ruptures leading to formation of erosive lesions⁴.

A diagnostic clinical test in evaluating patients with signs of oral ulcerations is known as Nikolsky's sign. The test is named after Pyotr Vasilyewich nikolsky, who first described this sign in 1896²⁸. Nikolsky's sign involves formation of a lesion after gentle mechanical manipulation (blowing air / applying pressure with mirror handle) on the involved tissue. Wet and dry nikolsky's sign are usually the two forms appreciated. Wet nikolsky's sign in associated with a glistening, moist, and exudative base of eroded skin, indicating an active disease. However, in the dry nikolsky's

sign, after the epidermis is separated, the base of eroded skin is relatively dry, indicative of re-epithelization underneath a remnant blister top²⁹. A positive Nikolsky's sign is not limited to PV, and Mucus membrane pemphigoid (MMP), toxic epidermal necrolysis, epidermolysis bullosa and staphylococcal scalded skin syndrome may also present with positive Nikolsky's sign³⁰.

A Danish dermatologist, Gustav Asboe-Hansen was the first to describe another peculiar sign (Asboe-Hansen sign) in PV in 1960³¹. Asboe-Hansen sign, also termed as blister-spread sign, refers to the peripheral extension of the blister when mechanical pressure is applied on the roof of the intact blister³².

ORAL MANIFESTATIONS

The oral mucosa is frequently involved early in the disease course, and may be the only involved site in few cases³³. 80-90% of affected patients with PV report oral lesions sometime during the disease process. However, the oral lesions may be the only manifesting feature in more than 60% patients¹¹. Oral lesions are initially vesiculobullous, readily burst readily, and new bullous

lesion develops as the older ones rupture and ulcerate³⁴. (Figure 2) The ulcerative and erosive lesions are the key manifestations and are seen mainly on the buccal mucosa, palate, and lips. (Figures 3-6) Pemphigus should always be given a place in the differential diagnosis of chronic, multiple oral erosions³⁵.

Gingival lesions initially manifest as isolated blisters or areas of tissue sloughing, but severe desquamative lesions may be appreciated in the advanced stages³⁶. (Figure 7) Positive Nikolsky's sign is seen, and few cases presents with desquamative gingivitis as the only presenting sign²⁴.

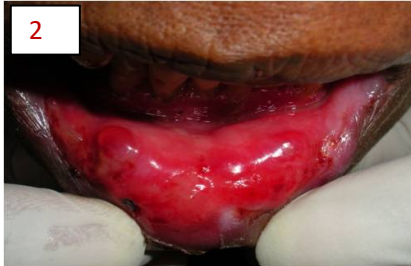

Figure 2- Fluid filled vesicles and bullae on lip.

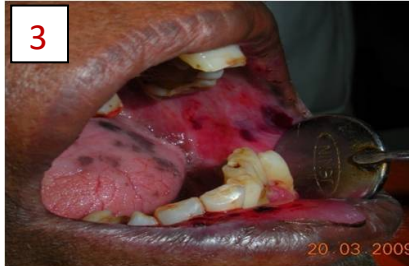

Figure 3,4- Ill defined erosive lesion on buccal mucosa.

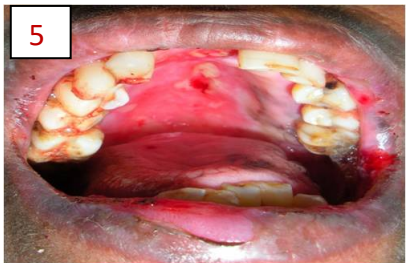
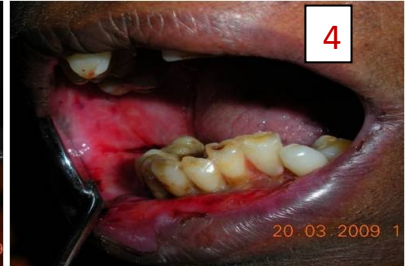
Figure 5- Ill defined erosive lesion on palate.

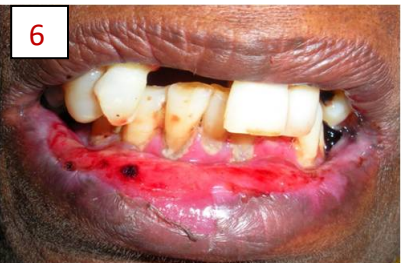

Figure 6- Erosive ulcerated lesion on lip till mucocutaneous junction.

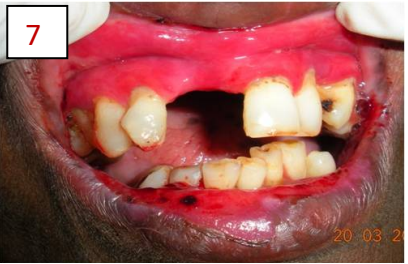

Figure 7- Desquamative gingivitis.

DIAGNOSIS

The diagnosis of Pemphigus vulgaris is based on 3 independent sets of criteria: clinical features, histology and immunological tests. Exclusive oral PV presents diagnostic dilemmas and the diagnosis is established using histopathologic and direct immunofluorescence (DIF) studies³⁶. Clinical diagnosis- Nikolsky's sign may serve as a diagnostic tool in PV patients, but this is neither completely sensitive nor specific³⁷.

Histological features- The classic histological feature seen in pemphigus is acantholysis, which is loss of cell-to-cell contact in the epithelial cell layers. In PV, intercellular edema results in dissolution of intercellular bridges and widening of intercellular spaces. This results in separation between cells and formation of blister above basal cell layer (supra basilar split)³⁸. (Figures 8,9)

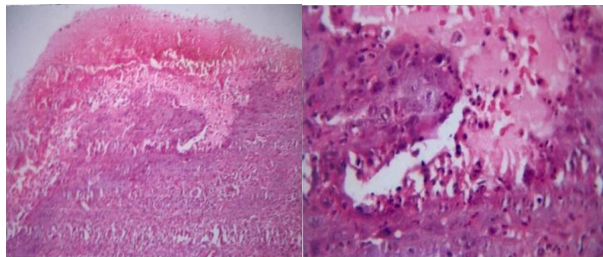


Figure 8 & 9- Characteristic suprabasilar split and acantholysis.

(Figure 2-9 Courtesy Hasan S, Ahmed S, Khan NI, Tarannum F. Pemphigus vulgaris—a case report and detailed review of literature. Indian Journal of Dentistry 2011; 2(3):113-119.

Tzanck preparation- The base of blister is scrapped and examined for acantholytic cells. The free floating ovoid or rounded acantholytic cells have an enlarged, hyperchromatic centrally or eccentrically placed nucleus. Basal cells have tight attachment to basal lamina but gets detached from one another, producing a characteristic tomb stone appearance³⁹. Relatively fewer inflammatory cells are seen in PV compared with other bullous diseases.

Compressed air test- Application of a stream of compressed air to the oral mucous membrane of gingival tissues may cause a shimmering of the outer tissues followed by formation of a bleb or blister.

Direct Immunofluorescence- Antibodies that complement various immunoglobulins, most commonly IgG are revealed¹². This reaction is found intracellularly in epithelium, and creates a distinctive direct immunofluorescence appearance, referred to as chicken wire effect. (Figure 10)

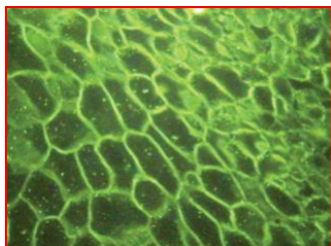


Figure 10. Immunofluorescence of pemphigus vulgaris showing chicken wire effect.

Indirect Immunofluorescence- can help determine the severity of antigen-antibody reaction and monitor treatment progress¹².

Upper gastrointestinal endoscopy- may be useful in identifying oesophageal involvement⁴⁰.

ELISA technique- Can detect Dsg1 & Dsg3 in serum samples¹¹.

Immunoprecipitation- At present, immunoprecipitation is regarded as the technique of choice for identifying the patient's autoantibody target antigens. In this context, desmoglein 3 is targeted in PV, while desmoglein 1 is targeted in pemphigus foliaceus (in skin)⁴¹.

TREATMENT

Periodontal therapy is an essential part of overall treatment of pemphigus. Oral hygiene maintenance is mandatory because the gingival involvement may present an exaggerated response to bacterial plaque. Oral lesions pose a therapeutic challenge due to chronic trauma to the surface epithelium during mastication.

The pharmacotherapy aims to combat the disease exacerbations as early as possible⁴². Corticosteroids have a proven efficacy as a therapeutic agent in PV patients, thereby, restoring the marked discrepancy of T₄:T₈ (helper T – T suppressor) ratio⁴³. In patients with non-progressing oral lesions, topical corticosteroids such as 0.05% fluocinolone acetonide or 0.05% clobetasol propionate are recommended^{44,45}. Patients on long term steroid treatment are monitored for weight gain and advised low salt, low fat, low calorie diet. PV patients are often prescribed Dapsone (125-150 mg daily) or tetracycline (2 g/day) and nicotinamide (1.5 g/day)⁴⁶.

Combination therapy: Combining corticosteroids with immune-suppressive agents (azathioprine, methotrexate, and cyclosporine) allows use of much smaller steroid doses, thus, reducing the steroid-related complications⁴³.

Plasminogen activators (tranexamic acid) prevent conversion of plasminogen to plasmin, and are quite beneficial in treating pemphigus⁴⁷. Other options are chlorambucil 0.1-0.15 mg/kg/day, cyclosporine 5-8 mg/kg/day, mycophenolate mofetil 30-45 mg/kg/day, and methotrexate 10-17.5 mg/week. Refractory cases are treated by rituximab, plasmapheresis to reduce the presence of antibodies in serum⁴⁸, or pulse therapy comprising intravenous cyclophosphamide combined with dexamethasone at high doses.

Intravenous Immunoglobulins: Proved successful & safe in steroid resistant PV⁴⁹.

Emerging therapies⁵⁰- Cholinergic agonists (modulates autoimmune response which require autoreactive helper T cells that regulate IgG isotope switching), Rituximab (Anti CD20 monoclonal antibody), Proteinase inhibitors, and chimeric molecules. Rituximab belongs to the class of biologicals and is a specific mouse and human chimeric monoclonal antibody. Binding of rituximab to CD 20 results in complement- and antibody-dependent cytotoxicity and subsequent apoptosis of

cells exhibiting this antigen²⁶. Chimeric molecules enables the recognition and elimination of autoimmune B cells which targets Dsg3 specific T cells⁵¹.

CONCLUSION

Pemphigus vulgaris, an autoimmune mucocutaneous disorder is typified clinically by thin walled flaccid vesicles and bullae, eventually leading to multiple erosive lesions, and histopathologically by intra-epithelial blisters. Oral lesions generally precede the cutaneous lesions and remain persistent for a relatively longer time due to unrelentless trauma. Early and accurate diagnosis of oral lesions is essential for an effective treatment protocol. Although, corticosteroids form the baseline of pharmacotherapy, newer treatment options are also being explored with excellent therapeutic potential.

REFERENCES

- Ahmed AR, Graham J, Jordon RE, Provost TT. Pemphigus: current concepts. *Annals of Internal Medicine* 1980;92(3):396-405.
- Becker BA, Gaspari AA. Pemphigus vulgaris and vegetans. *Dermatology Clinics* 1993; 11(3):429-453.
- Lever WP. Pemphigus and pemphigoid: a review of the advances made since 1964. *Journal of American Academy Dermatology* 1979;1(1):2-31.
- Fitzpatrick TB, Eisen AZ, Wolff K, Freedberg IM, Austen KF, editors. 1993. *Dermatology in general medicine*, 4th ed. Vol I and II. New York: McGraw-Hill, Inc.p. 577-669.
- Anhalt G, Kim S, Stanley J et al. Paraneoplastic pemphigus: an autoimmune mucocutaneous disease associated with neoplasia. *The New England Journal of Medicine* 1990;323(25):1729-1735.
- Morioka S, Naito K, Ogawa H. The pathogenic role of pemphigus antibodies and proteinase in epidermal acantholysis. *Journal of investigative Dermatology* 1981;76(5): 337-41.
- Jones JCR, Arun J, Staehelin LA, Goldman RD. Human antibodies against desmosomes ; possible causative factors in pemphigus. *Proceedings of the National Academy of Sciences of the United States of America* 1984;81(9): 2781 – 2785.
- korman N. Pemphigus. *Journal of American Academy Dermatology* 1988;18(6):1219 – 38.
- Shafer WG, Hine MK, Levy BM. In: Shafer's Textbook of Oral Pathology 5th ed. New Delhi: Elsevier 2006.
- Ahmad AR, Moy R. Death in Pemphigus *Journal of American Academy Dermatology* 1982;7(2): 221 -228.
- Martin S Greenberg, Micheal Glick, Jonathan Ship. *Burkitts Oral Medicine Diagnosis and Treatment* 11th edition. BC Decker Inc, 2008.
- Scully C, Challacombe SJ. Pemphigus vulgaris: Update on etiopathogenesis, oral manifestations and management. *Critical Reviews in Oral Biology and Medicine* 2002;;13(5):397-408.
- Brenner S, Bialy-Golan A, Ruocco V. Drug-induced pemphigus. *Clinical Dermatology* 1998; 16(3):393-397.
- Tur E, Brenner S. Diet and pemphigus. In pursuit of exogenous factors in pemphigus and fogo selvagem. *Archives of Dermatology* 1998;134(11):1406-1410.
- Ruocco V, Brenner S, Lombardi ML. A case of diet related pemphigus. *Dermatology* 1996;192(4):373-374.
- Ruocco E, Aurelia A, Ruocco V. Precautions and suggestions for pemphigus patients. *Dermatology* 2001; 203(3): 201-207.
- Ruocco V, Wolf R, Ruocco E, Baroni A. Viruses in pemphigus: a casual or causal relationship? *International Journal of Dermatology* 1996;35(11):782-784.
- Takahashi I, Kobayashi TK, Suzuki H, Nakamura S, Tezuka F. Coexistence of pemphigus vulgaris and herpes simplex virus infection in oral mucosa diagnosed by cytology,

- immunohistochemistry, and polymerase chain reaction. *Diagnostic Cytopathology* 1998;19(6):446-450.
19. Goon AT, Tay YK, Tan SH. Pemphigus vulgaris following varicella infection. *Clinical and Experimental Dermatology* 2001; 26(8):661-663.
20. Memar OM, Rady PL, Goldblum RM, Tyring SK. Human herpesvirus-8 DNA sequences in a patient with pemphigus vulgaris, but without HIV infection or Kaposi's sarcoma. *The Journal of Investigative Dermatology* 1997;108(1):118-119.
21. Jang HS, Oh CK, Lim JY, et al. Detection of human herpesvirus 8 DNA in pemphigus and chronic blistering skin diseases. *Journal of Korean Medical Sciences* 2000;15:442-448.
22. Brenner S, Tur E, Shapiro J, et al. Pemphigus vulgaris: environmental factors. Occupational, behavioral, medical, and qualitative food frequency questionnaire. *International Journal of Dermatology* 2001; 40(9):562-569.
23. Presland R, Dale BA. Epithelial structural proteins on the skin and oral cavity: function in health and disease. *Critical Reviews in Oral Biology and Medicine* 2000;11(4):383-408.
24. Endo H, Rees TD, Matsue M et al. Early detection and successful management of oral pemphigus vulgaris: a case report. *Journal of Periodontology* 2005;76(1): 154-160.
25. Endo H, Rees TD, Hallmon WW, et al. Disease progression from mucosal to mucocutaneous involvement in a patient with desquamative gingivitis associated with pemphigus vulgaris. *Journal of Periodontology* 2008; 79(2): 369-375.
26. Siddiqui S, Haroon MA, Hasan S, Khalid A. To Determine Desmoglein Compensation Theory: An explanation for early appearance of oral lesions as compared to skin lesions in Pemphigus vulgaris. *International Archives of BioMedical and Clinical Research* 2016; 2(3): 13-17.
27. Sirios D, Leigh JE, Sollecito TP. Oral pemphigus vulgaris preceding cutaneous lesions, Recognition and diagnosis. *Journal of American Dental Association* 2000;131(8): 1156-1160.
28. Nikolsky PV. The materials on the study of pemphigus foliaceus cazenavi. Thesis, The St. Vladimir emperor university of kiev, Kiev (in russian). 1896
29. Bharathi U, Naresh Lingaraju, Srisha Basappa, Mahesh MS. Oral Pemphigus Vulgaris: A Case Report and Review. *IOSR Journal of Dental and Medical Sciences* 2014;13(11):24-29.
30. Hasan S, Ahmed S, Khan NI, Tarannum F. Pemphigus vulgaris—a case report and detailed review of literature. *Indian Journal of Dentistry* 2011; 2(3):113-119.
31. Asboe-Hansen G. Blister-spread induced by finger-pressure, a diagnostic sign in pemphigus. *The Journal of Investigative Dermatology* 1960;34:5-9.
32. Grando SA, Grando AA, Glukhenky BT, et al. History and clinical significance of mechanical symptoms in blistering dermatoses: a reappraisal. *Journal of American Academy Dermatology* 2003;48(1):86-92.
33. Lamey PJ, Rees TD, Binnie WH, et al. Oral presentations of pemphigus vulgaris and its response to systemic steroid therapy. *Oral Surgery Oral Medicine and Oral pathology* 1992;74(1) ;54-57.
34. Sciubba JJ. Autoimmune aspects of pemphigus vulgaris and mucosal pemphigoid. *Advances in Dental Research* 1996;10(1):52-56.
35. Femiano F, Gombos F, Nunziata M, Esposito V, Scully C. Pemphigus mimicking aphthous stomatitis. *Journal of Oral pathology and Medicine* 2005;34(8);508 – 510.
36. Mignogna MD, Lo Muzio L, Bucci E. Clinical features of gingival pemphigus vulgaris. *Journal of Clinical Periodontology* 2001; 28(5):489-493.
37. Hasan S, Khan NI, Sherwani OA et al. Pemphigus Vulgaris: An Insight on conventional and emerging treatment modalities. *International Research Journal of Pharmacy* 2013; 4(3):8-14.
38. Uzun S, Durdu M. The specificity and sensitivity of Nikolsky sign in the diagnosis of pemphigus. *Journal of American Academy Dermatology* 2006;54(3): 411-415.
39. Hashimoto K; Lever WF. An electronic microscopic study of pemphigus vulgaris of the mouth and skin with special reference to the inter-cellular cement. *Journal of Investigative Dermatology* 1967; 48:540-555.
40. Director W. Pemphigus vulgaris: A clinicopathological study. *AMA Archives of Dermatology and Syphilology* 1992;65(2);155-169.
41. Galloro G, Mignogna M, de Werra C, et al. The role of upper endoscopy in identifying esophageal involvement in patients with oral pemphigus vulgaris. *Digestive and Liver diseases* 2005;37(3):195-199.
42. Weinberg MA, Insler MS, Campen RB. Mucocutaneous features of autoimmune blistering diseases. *Oral Medicine, Oral Pathology, Oral Radiology, and Endodontics* 1997;84(5):517-534.
43. López-Jornet P, Bermejo-Fenoll A. Treatment of pemphigus and pemphigoids. *Medicina Oral , Patologia Oral y Cirugia Bucal*. 2005;10(5):410-411.
44. Carson PJ, Hameed A, Ahmad AR. Influence of treatment on the clinical course of pemphigus vulgaris *Journal of American Academy Dermatology* 1996; 34:645- 652.
45. Hashimoto T. Treatment strategies for pemphigus vulgaris in Japan. *Expert Opinions in Pharmacotherapy* 2008;9:1519-1530.
46. Prajapati V, Mydlarski PR. Advances in pemphigus therapy. *Skin Therapy Letter* 2008;13(3):4-7.
47. Knudson RM, Kalaaji AN, Bruce AJ. The management of mucous membrane pemphigoid and pemphigus. *Dermatologic Therapy* 2010;23(3):268-80.
48. Wilkinson JC, Smith CA, Sutler MM, et al. Role of plasminogen activator in pemphigus vulgaris. *The American Journal of Pathology* 1989;134(3);561-569.
49. Aoyama Y, Nagasawa C, Nagai M, Kitajima Y. Severe pemphigus vulgaris: successful combination therapy of plasmapheresis followed by intravenous high-dose immunoglobulin to prevent rebound increase in pathogenic IgG. *European Journal of Dermatology* 2008;18:557- 60.
50. Akerman L, Mimouni D, David M. Intravenous immunoglobulins for treatment of pemphigus. *Clinical Reviews in Allergy and Immunology* 2005;29(3);289 – 295.
51. Scully C, Mignogna M. Oral Mucosal Diseases: Pemphigus. *The British Journal of Oral and maxilla-facial surgery* 2008;46(4); 272-277.

Cite this article as:

Shamimul Hasan et al. Pemphigus vulgaris: An update on etiopathogenesis, clinical manifestations, diagnosis and treatment modalities. *Int. Res. J. Pharm.* 2019;10(3):1-6
<http://dx.doi.org/10.7897/2230-8407.100369>

Source of support: Nil, Conflict of interest: None Declared

Disclaimer: IRJP is solely owned by Moksha Publishing House - A non-profit publishing house, dedicated to publish quality research, while every effort has been taken to verify the accuracy of the content published in our Journal. IRJP cannot accept any responsibility or liability for the site content and articles published. The views expressed in articles by our contributing authors are not necessarily those of IRJP editor or editorial board members.